

Mitral Valve Repair

Mitral Valve Repair versus Replacement:

A successfully repaired heart valve is expected to have a better outcome than replacing a damaged heart valve with a man-made valve. The life expectancy of a repaired valve is much longer when compared to a bioprosthesis valve used in replacement. A repaired heart valve can last for 10 years at the minimum and in many cases it can last a lifetime. The advantages of mitral valve repair over replacement are twofold:

(1) Avoidance of Coumadin:

More importantly for the younger patients, a repaired valve avoids the need of anti-coagulation with Coumadin or warfarin that is obligated in the use of mechanical valve. This is a major advantage over mechanical valves associated thromboembolism (clot formation leading to stroke and valve malfunction) and spontaneous bleeding complications.

(2) Preservation of heart function:

Furthermore, many clinical studies and laboratory studies have demonstrated the preservation of heart function with repair, in opposed to the 15-20% reduction of left ventricular function when the mitral valve is replaced by an artificial valve. This is due to the preservation of the anatomical interaction of the ventricular muscle and the pulley mechanism of the valve in repair; they are severed in valve replacement.

However, a small percentage of mitral valve cases are not suitable for repair and replacement will be the surgery of choice. The decision to repair or to replace a heart valve is based on complex factors and is unique in each individual patient. The cardiothoracic surgeon will carefully determine the type of surgery considering all the factors presented.

Complex mitral valve repair represents the maturity of a cardiac surgical program. In 2007, the number of mitral valve repairs performed at Downstate Medical Center increased by 71% compared to the average of the previous four years. With the adaptation of new technology, equipments, and personnel, the **Downstate cardiac surgery program** aims to expand this service to include all treatment options for complex heart valvular diseases.

Guideline for Surgical Mitral Valve Repair

The Society of Thoracic Surgeons, American College of Cardiology, and the American Heart Association have guidelines which list the factors determining timing of surgery for degenerative mitral regurgitation¹:

- a. Heart failure symptoms
- b. Enlarged heart chamber
- c. Impaired pump function
- d. Pulmonary hypertension
- e. Atrial fibrillation

a. Patients with symptoms

Patients with symptoms of congestive heart failure and moderate to severe mitral regurgitation should be referred and considered for surgical repair. Delay in surgical treatment compromises the patients' long term survival, especially when surgery is postponed till the patients develop advanced stages of symptoms (New York Heart Association Class III or IV).²

Symptomatic patients with lesser degree of demonstrable mitral regurgitation on echocardiogram are recommended to undergo additional testing. If the patients' (1) mitral regurgitation is found to be worsened, or (2) the ejection fraction is found to be decreased after exercise in stress echocardiogram, surgical intervention is also recommended.³

b. and c. Patients with no symptoms, but with enlarged heart and/or decreased heart function:

Patients may not notice significant symptoms despite having long standing and severe mitral regurgitation especially in the younger age groups. It is possible that younger patients have a greater compensatory mechanism, and the older patients simply adjust their daily activities based on their exertion tolerance. Therefore, it is not uncommon to find patients with severe mitral regurgitation on echocardiogram and other associated indexes but they claim to have minimal or no symptoms. The counseling of these patients is challenging for the physicians, because their long term survival definitely benefit from surgical repair when done in a timely fashion. Surgery is recommended for patients with left ventricular dilatation end systolic diameter more than 45 mm, and/or lower than normal ejection fraction (<60%) of no other cause, i.e. ischemic disease. Therefore, the asymptomatic patients with severe mitral regurgitation need to be followed closely with serial echocardiogram on the changes in the dimension and the function of the left ventricle.

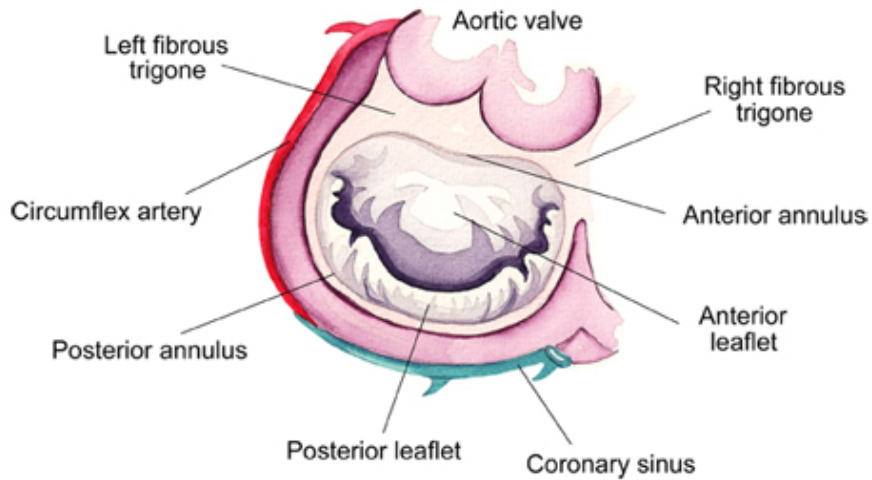
d. and e. Atrial fibrillation and pulmonary hypertension.

The development of atrial fibrillation and/or pulmonary hypertension in the absence of other causes denotes the chronicity and severity of the mitral valve regurgitation, and they are generally clear indication for mitral valve intervention preferably a repair.

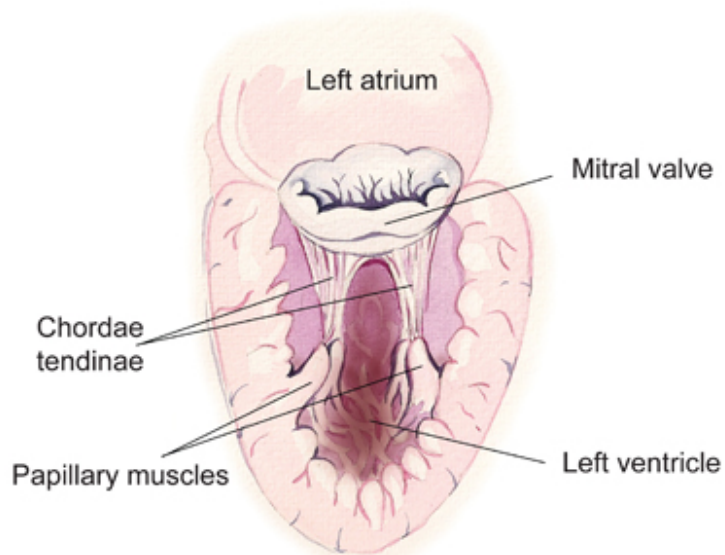
Types of Mitral Valve Repairs:

The mitral valve of the human heart is likened to a pair of swinging kitchen doors (see figures 1 and 2) It is composed of the two doors (mitral valve leaflets), the door frame (mitral valve annulus), hinges (mitral valve commissures/ fibrous trigones), and the door stoppers (the chordae tendinae). The mitral valve becomes incompetent or regurgitant ("leaky") when any one or a combination of these components of the "one way swinging doors" is defective. The surgical repair is designed and tailored to restore these damaged parts.

Figure 1: Mitral valve components

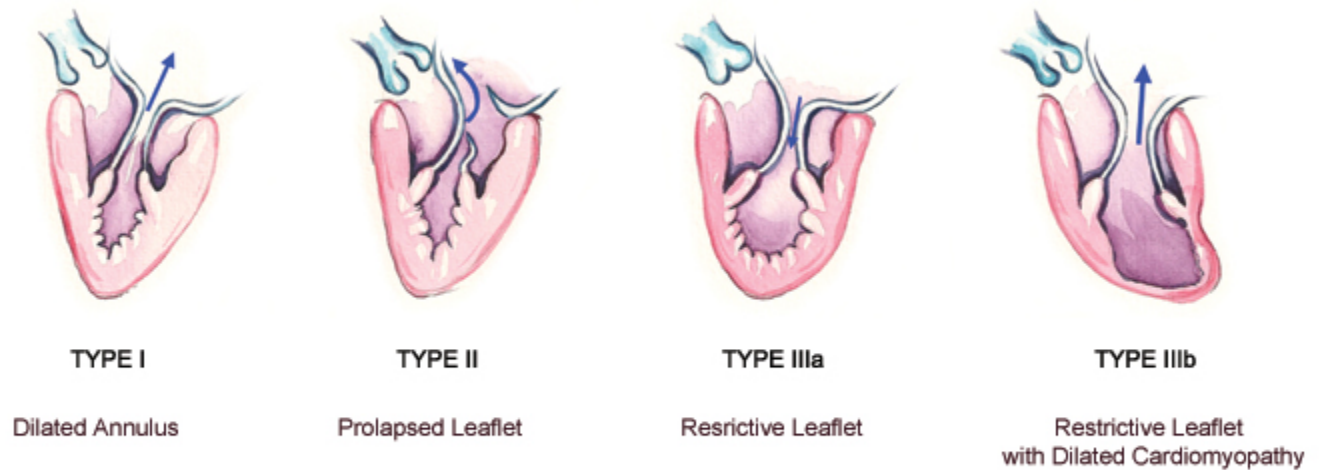


Eun H. Ko



Eun H. Ko

Figure 2. Carpentier classification of mitral valve regurgitation

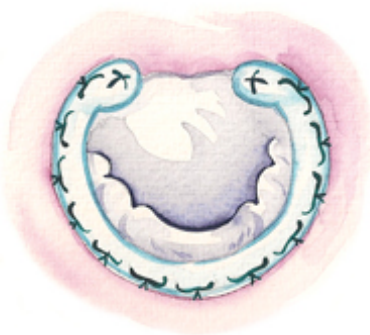

Eun H. Ko

(1) Annuloplasty

In this common clinical scenario, the only defect is an enlarged annulus that is too large for the mitral valve leaflets. In effect, the leaflets do not touch adequately (inadequate coaptation) to maintain competency. This technique is designed to correct the defect to re-size the annulus to fit the leaflets or to re-size the annulus to fit the size of the anterior mitral valve leaflet. This is the most basic mitral valve repair and it is often used to reinforce the other types of repairs.

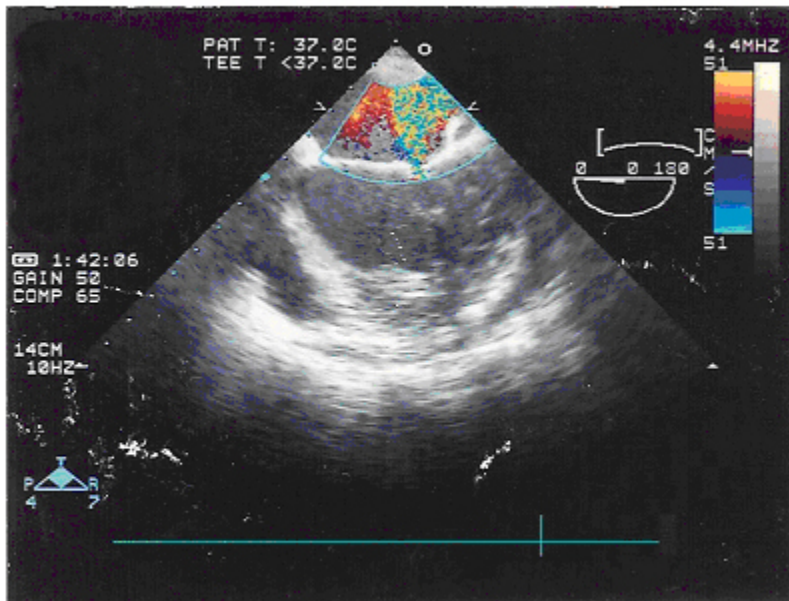
Figure 3. Mitral annuloplasty



Eun H. Ko

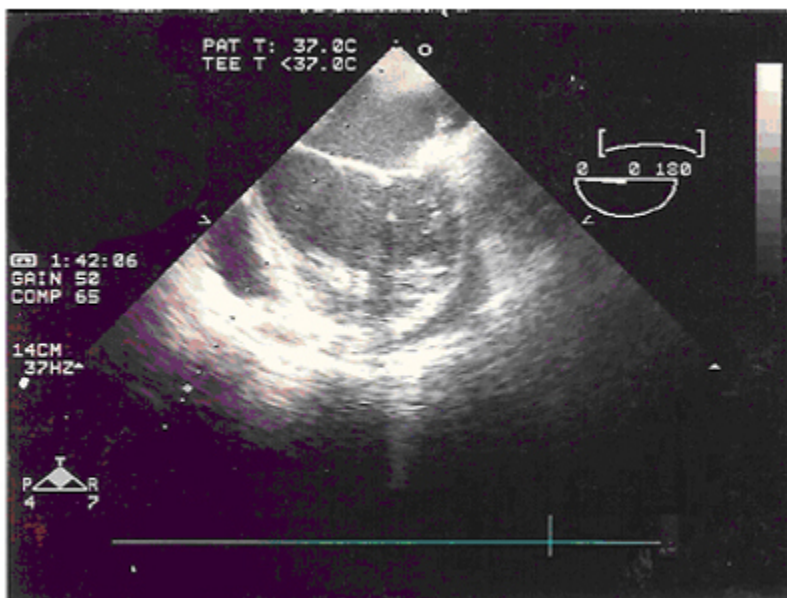
Below is an echocardiogram of a regurgitant mitral valve due to a dilated annulus causing a central leak as represented by the mosaic of color doppler flow.

Figure 4. Dilated annulus with central regurgitation



After the annuloplasty, there was no residual leak as represented by the absence of the color pattern through the valve during the systolic phase of the cardiac cycle.

Figure 5. No residual leaks after annuloplasty



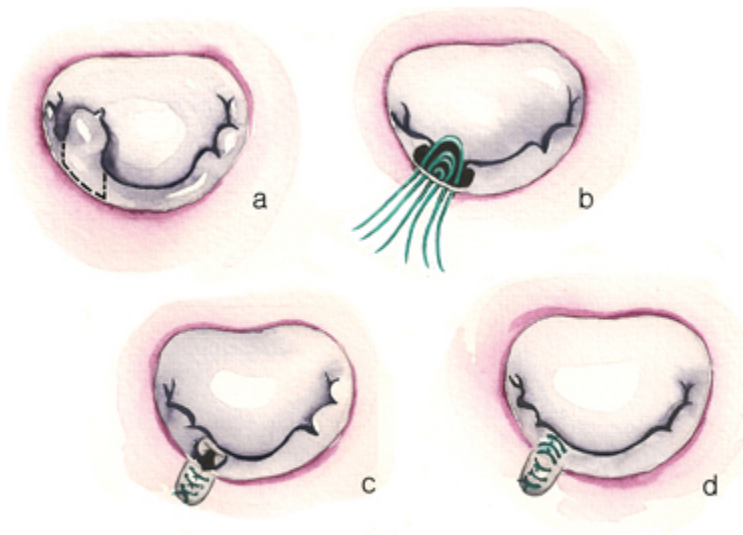
The use of intra-operative trans-esophageal echocardiogram (T.E.E.) has revolutionize the surgeon's ability to repair the mitral valve. This technology has allowed the surgeon to visualize the defects responsible for the regurgitation in real time while the heart is beating in its normal anatomic positions. Furthermore, it is vital in assessing the result of the surgeon's repair immediately in the operating room.

(2) Leaflet resection for "Flailed" or "Prolapsed" mitral valve

The edges of the two leaflets are attached to the papillary muscle of the left ventricle by strands called chordae teninae. The flailed segment of the valve is simply resected and the edges of the normal segments are sutured together (figure 6). It is the most reproducible type of repair of this particular lesion and it is the most common repair world-wide.

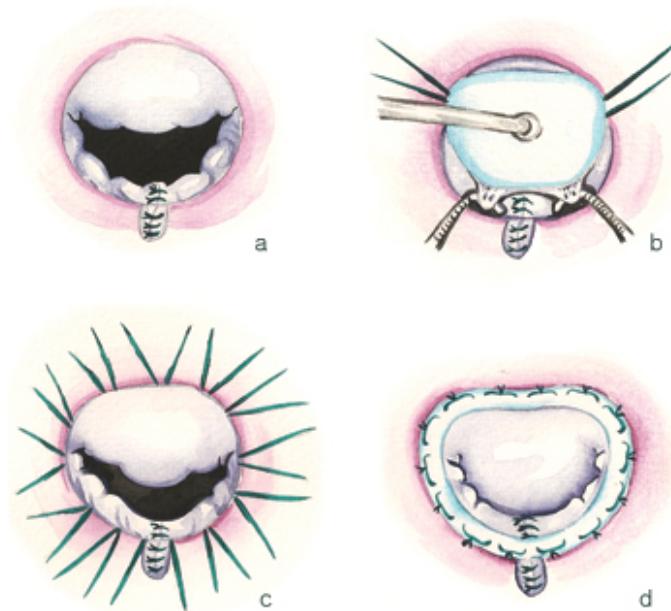
Most often, the repair if reinforced in an annuloplasty ring as depicted in figure 7.

Figure 6. Quadragular resection of posterior leaflet



Eun H. Ko

Figure 7. Annuloplasty to reinforce leaflet resection

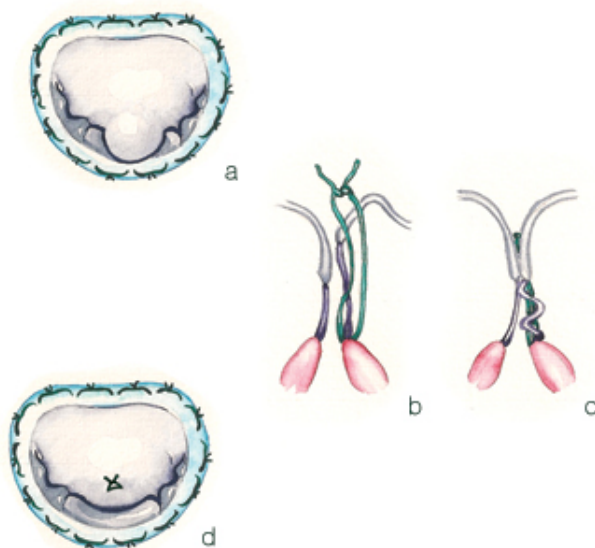


Eun H. Ko

(3) Artificial Chordal Replacement

In situations where the prolapsed leaflet segment is due to attenuated (stretched) chordae tendinae, sutures (usually Gortex) is used to re-attached the prolapsed segments with accurately measured lengths to re-establish appropriate coaptation of the two leaflets as shown in figure 8. Often, multiple Gortex sutures placement is required to obtain competency

Figure 8. Gortex chordal replacement

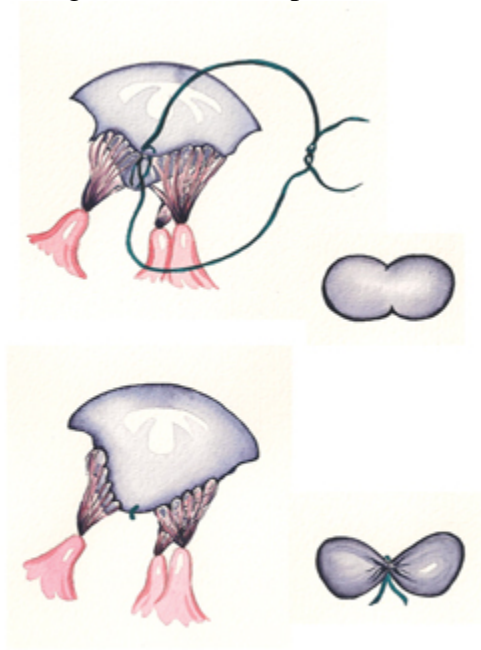


Eun H. Ko

(4) Alfieri Repair:

As demonstrated in figure 9, in certain situations strategic sutures placed to bring the two leaflets together may restore the adequate closure of the valve during systole. Although this technique works well in specific situation, it is the only technique that does not lead to normal anatomy and function of the human valve. Therefore, its use is controversial and is limited to a minority of the repairs.

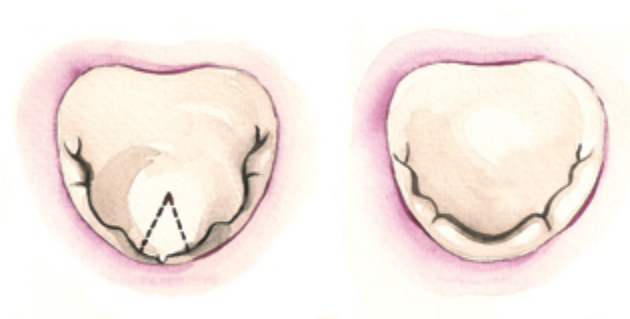
Figure 9. Alfieri repair



Eun H. Ko

(5) Triangular Anterior Leaflet Resection:

Although anterior leaflet repairs were not successful for decades, the recent enhanced understanding of the pathophysiology learned from high definition transesophageal echocardiogram has allowed the surgeons to recognize the exact nature of the lesions and be able to perform very targeted repair to produce a competent valve at the end.



Eun H. Ko

Philosophy of Mitral Valve Repair:

The complexity of the mitral valve repair requires an extended knowledge of the mitral valve anatomy and physiology in combination of a deep experience in performing the repair. The depth of the surgeon's experience allows a tailored approach in solving the particular patient's problem that seems to be unique in every case. The tailored approach usually requires a combination of repair techniques that leads to a completely competent valve at the end.

1. Journal of Heart Valve Disease 1998;7(6):672-707.
2. Circulation 1999;26:99(3), 400-5
3. Echocardiography 2004;21(5):451-8